


Chapter 1



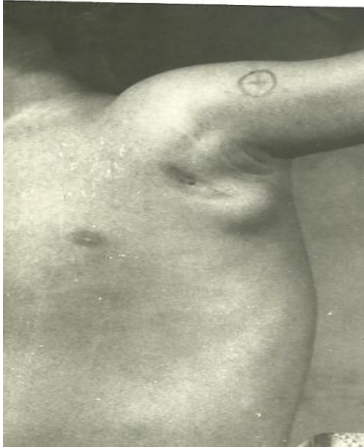Skin, Scalp and Face

1.1 Tuberculosis; BCG

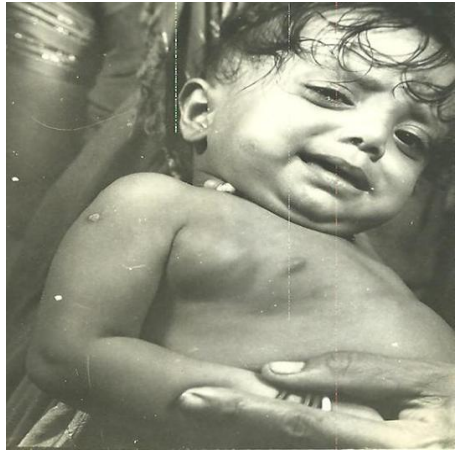Inoculation of infants by BCG is a universally accepted method of protection against tuberculosis. BCG is a live attenuated strain of the bacillus *Mycobacterium* and acts as an antigen. Recipient develops antibodies and active immunity against tuberculosis.

In rare cases, however if antibodies are already circulating in infant's blood, derived most likely from maternal blood, then a reaction develops, leading to formation of local and regional cold abscesses.

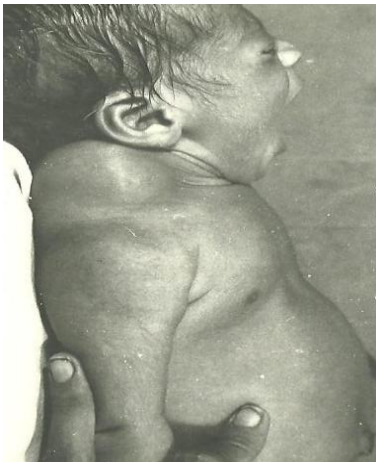Usually they are seen at the inoculation site or in regional lymph nodes such as in the axilla (1.1a, 1.1b) and supraclavicular area (1.1c). These may even track down to pre-sternal region (1.1d).



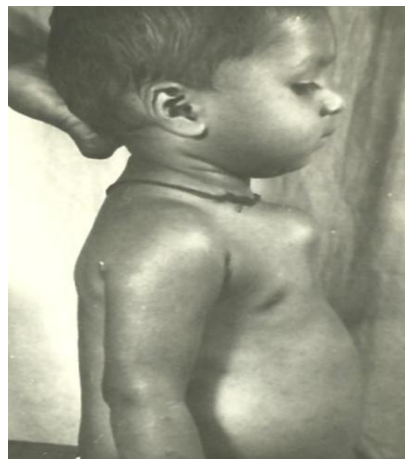1.1a



1.1b



1.1c

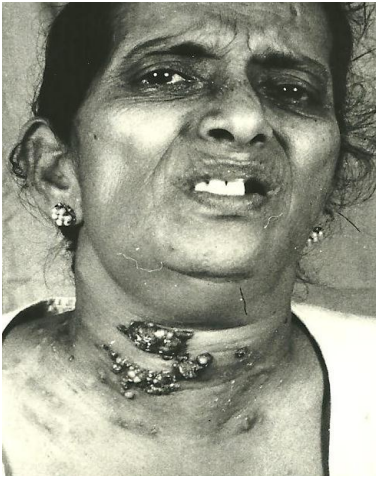

1.1d

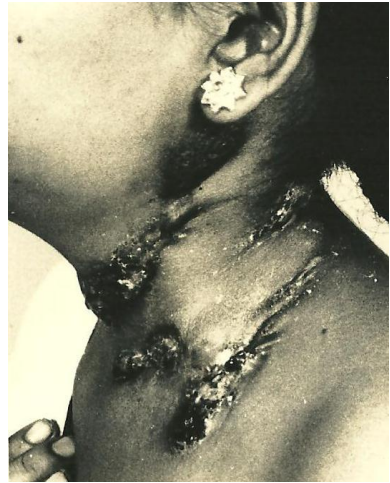1.2 Cutaneous Tuberculosis

Tuberculosis is a disease that affects primarily the lymphatic system. When subcutaneous and sub-fascial lymph nodes as in neck (1.2a, 1.2b), axilla and supracondylar area of arm (1.2c), and inguinal region (1.2d) are affected, cold abscesses and ‘Collar stud’ abscesses form.

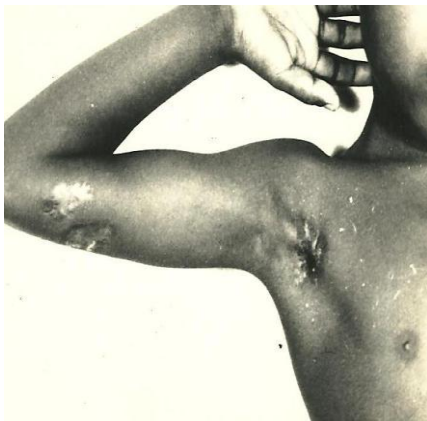If these break down and rupture, either multiple sinuses (1.2a, 1.2b, 1.2c) or chronic non-healing ulcers (1.2d) form with typical undermined edge.



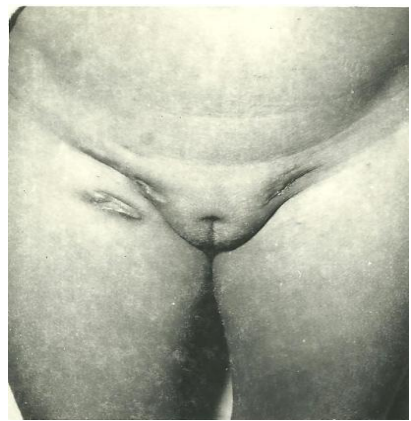1.2a



1.2b



1.2c



1.2d

1.3 Haemangioma

Hemangioma is a form of vascular anomaly, usually seen in infancy and childhood. They may disappear with time or may continue to grow slowly till adult age. If asymptomatic, then the facial asymmetry may be the only cosmetic concern and can be ignored by the patient. Symptomatic lesions should be evaluated with ultrasound and MRI for their extent and involvement of adjacent structures.

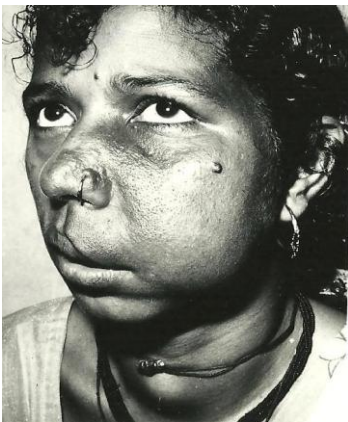1.3a and 1.3b show patients with hemangiomas of the right face while 1.3c and 1.3d are the pictures of hemangiomas of the left side of the face.



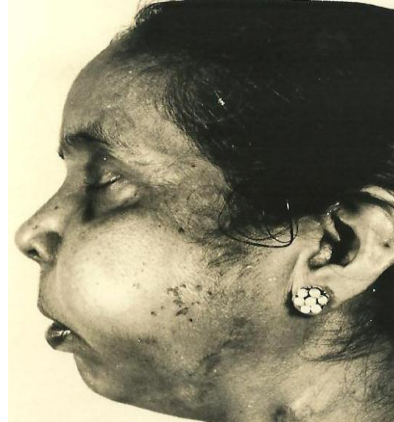1.3a



1.3b



1.3c



1.3d

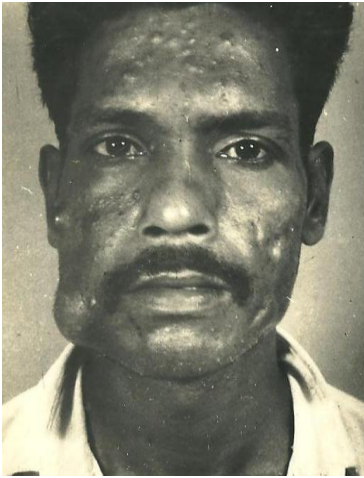
1.4 Subcutaneous Swellings

Von Recklinghausen's disease is the name given to multiple neurofibromatosis (1.4a, 1.4b).

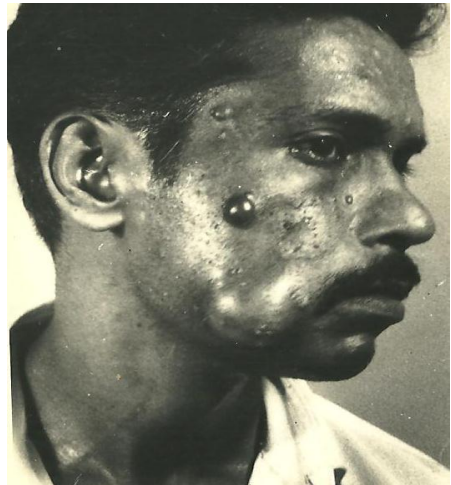
Subcutaneous neurofibroma affects nearly every part of the body. They may also be found in cavities such as intracranial, mediastinal, retroperitoneal, intraspinal and intra-articular areas.

Plexiform neurofibromatosis affects face where large, pendulous benign lesions hang down and may cover the face.

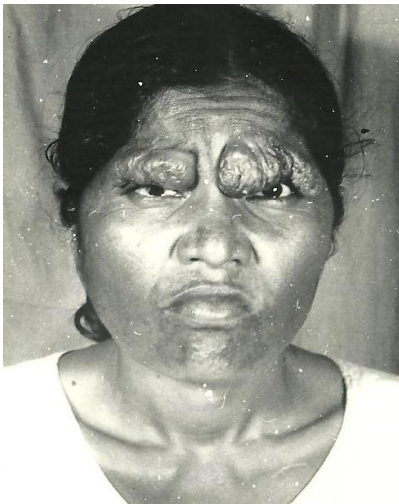Other conditions of face that mimic such lesions are myxomatous deposits in the periorbital area (1.4c) and Dercum's disease, plexiform neuro-lipomatosis (1.4d).



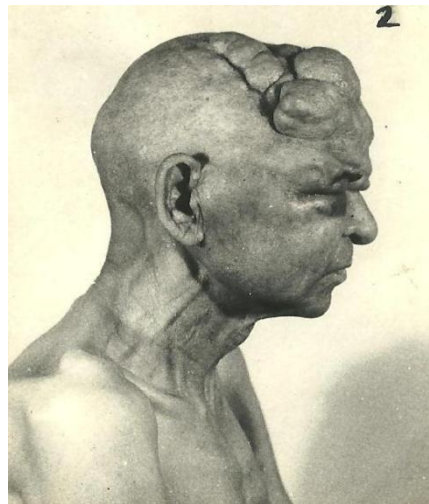
1.4a



1.4b



1.4c



1.4d

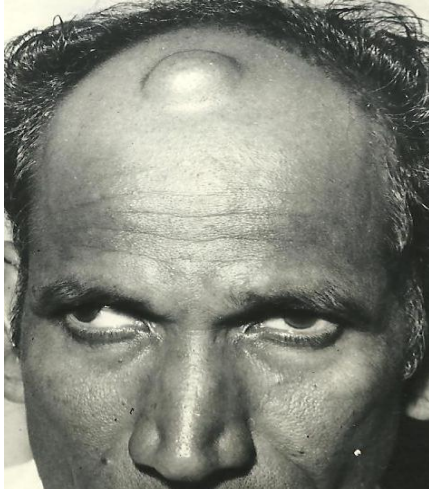
1.5 Sebaceous Cysts

Sebaceous cysts, [renamed by pathologists as epidermal cysts] are ‘Retention cysts’ of sebaceous glands, situated at the base of hair follicles. Their function is to secrete thin oily ‘Sebum’ is essential to lubricate the hair so that they do not break and fall down prematurely.

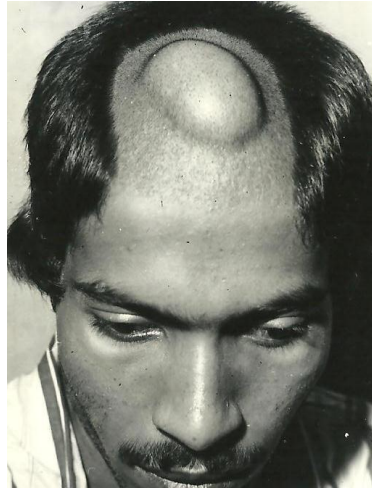
If the minute opening of the gland’s duct is blocked, the gland blows up as a cyst containing thick inspissated cheesy sebum. In fair skinned people a black spot called the “Punctum” can be seen over the cyst. This represents the site from where the hair fell. Being part of the epidermis, the skin over the cyst cannot be pinched away from the cyst wall, unlike in other subcutaneous cysts.

It is obvious that they are common in hairy areas like scalp, face, axilla and groin and are usually multiple (1.5a, 1.5b).

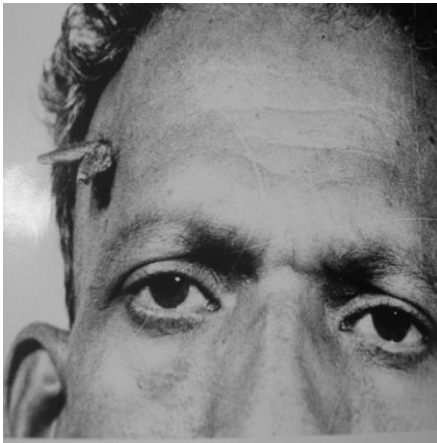‘Sebaceous horn’ (1.5c, 1.5d) is extremely rare complication of sebaceous cysts. Thick cheesy material continues to protrude slowly, keeps drying up and if not removed takes the shape of the hard thorny projection, miniature replica of ‘Horns’ seen in cattle.



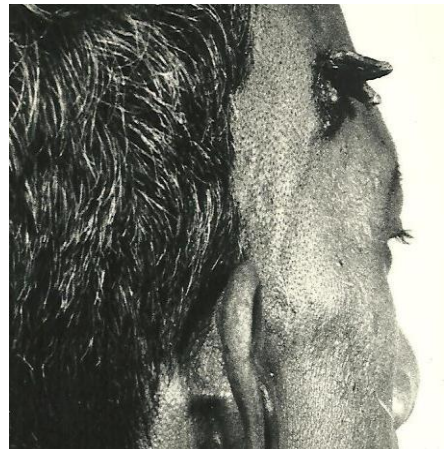
1.5a



1.5b



1.5c



1.5d

1.6 Keloids

Keloid is an aberration of the healing process.

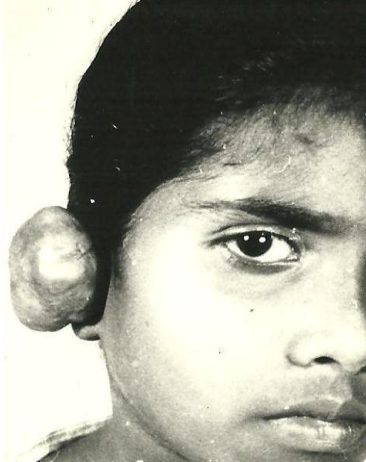Healing starts immediately following tissue damage. In superficial wounds of the skin, it includes formation of granulation tissue and regeneration of epithelium. This process stops by inherent internal mechanism once optimal healing is reached.

At times, however growth of granulation tissue and the epithelium continues, and leads to formation of hypertrophic scars. Except for cosmetics, these are harmless and asymptomatic.

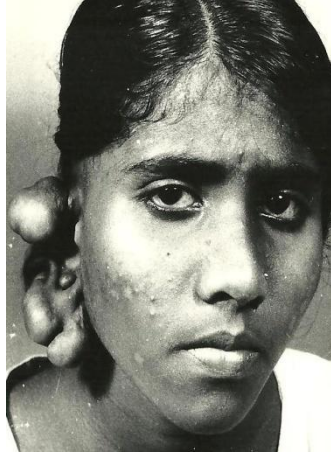In some cases activity of granulation tissue continues unstopped into the deeper tissues and leads to symptoms of burning pain and itching. Even after excision, activity and the scars recur and become very difficult to eradicate.

Keloids may take two forms.

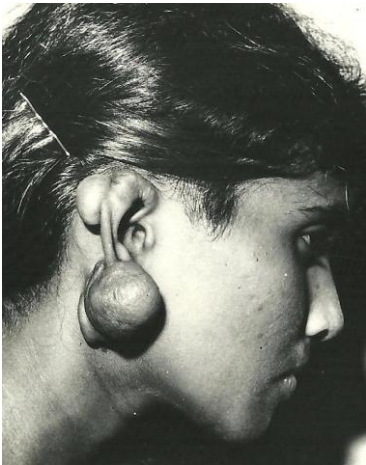
Outward slow growth may take place at the site of even minute puncture such as piercing of skin of ears, nose etc. These are common sites for such asymptomatic keloids (1.6a, 1.6b, 1.6c, 1.6d). The another form is symptomatic keloids.



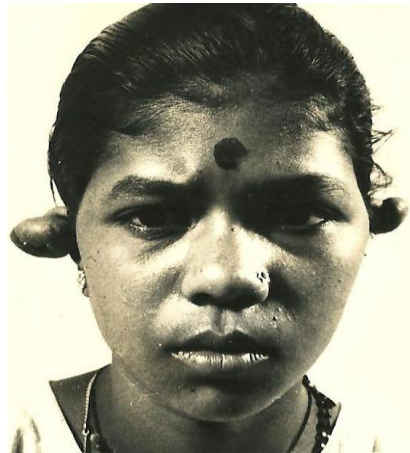1.6a



1.6b



1.6c



1.6d

1.7 Keloids [Contd.]

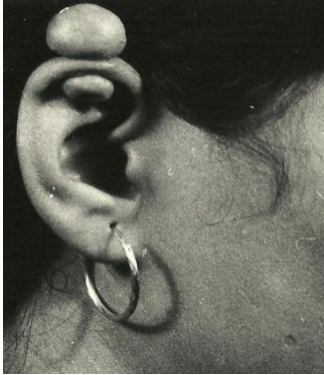
As mentioned earlier, asymptomatic keloids are common on piercing sites on ears (1.7a, 1.7b).

Another form of keloids may grow even without any obvious injury (1.7c, 1.7d).

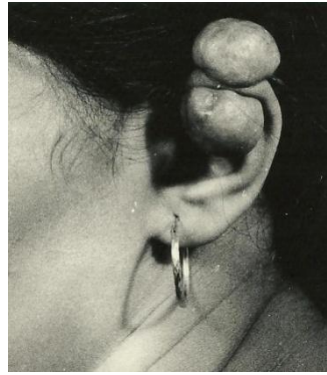
Their main growth is outwards as well as horizontally and inwards deep into dermis and subcutaneous tissues. These are very vascular and, angry looking, symptomatic and prone to recurrence.

Dark skin and African origin are associated with keloids.

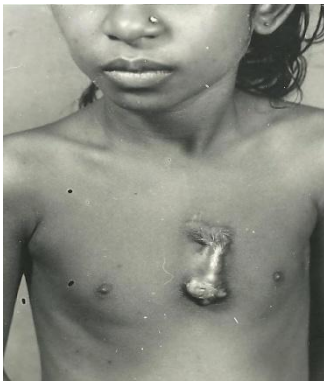Exact etiology is unknown, but genetic factors may be responsible for their development and behavior.



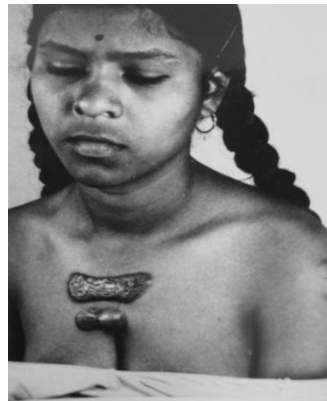1.7a



1.7b



1.7c



1.7d

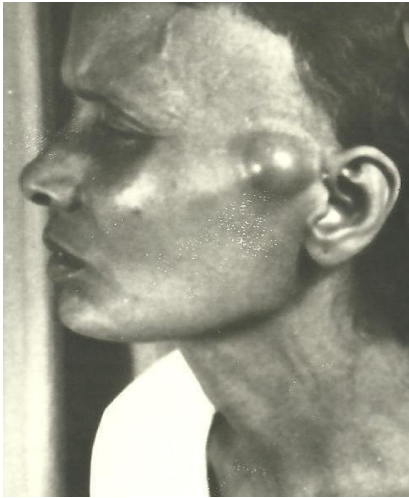1.8 Dermoids

Dermoids are the lesions that contain derivatives of two germinal layers.

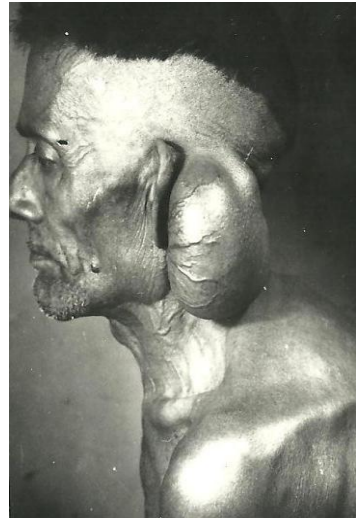Sequestration dermoids are the commonest. They are congenital, superficial and cystic, and contain epidermal and mesodermal elements. They are found at the sites of fusion of bony plates such as pre and post auricular regions (1.8a, 1.8b), and midline on the scalp. (1.8c).

Implantation dermoids are acquired lesions, usually seen in webs of fingers in barbers, but rarely can occur in the foot. (1.8d)

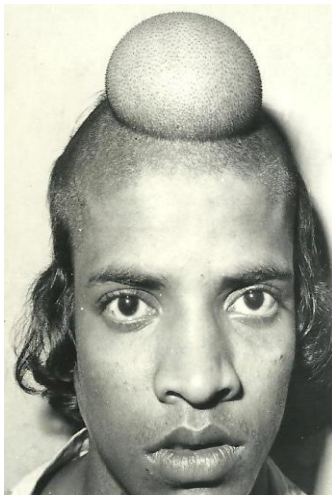
New formation dermoids are benign tumors and occur in the ovaries and testes.



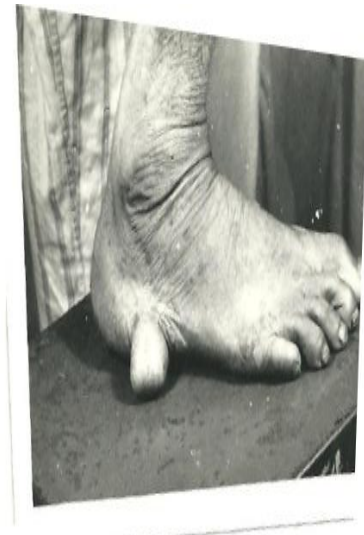1.8a



1.8b



1.8c



1.8d

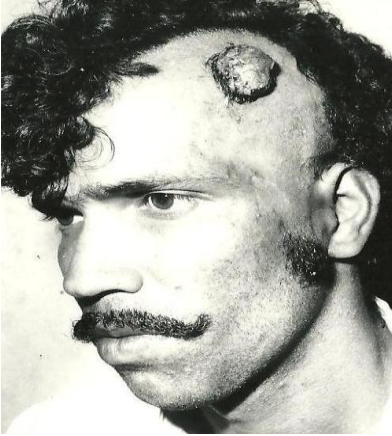1.9 Lesions of Face and Neck

Kerato-acanthomas may vary in size, may be single or multiple, may ulcerate, and although benign, may mimic serious carcinomatous ulcers (1.9a).

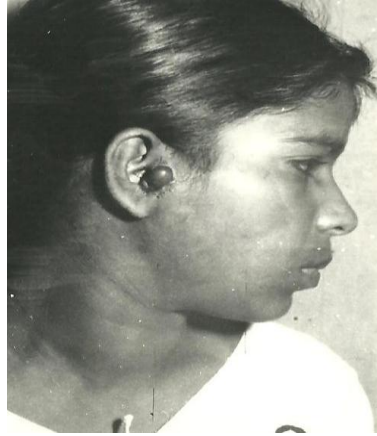In preauricular area, cystic lesions are either preauricular cyst or dermoid. Dark pigmented lesion in this area usually is a haemangiomatic malformation (1.9b).

Common long-standing swellings in the neck, other than are the lymph gland or cold abscesses. A large lipoma may mimic a cystic lesion, as in this case (1.9c).

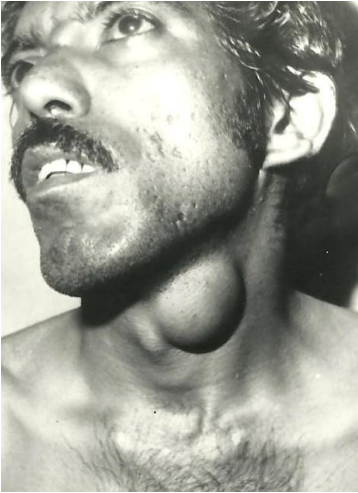
Such lipomas can be multiple (1.9d).



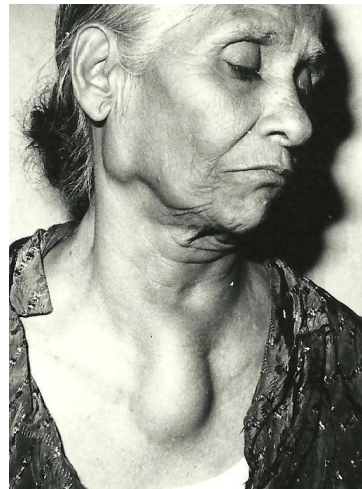1.9a



1.9b



1.9c



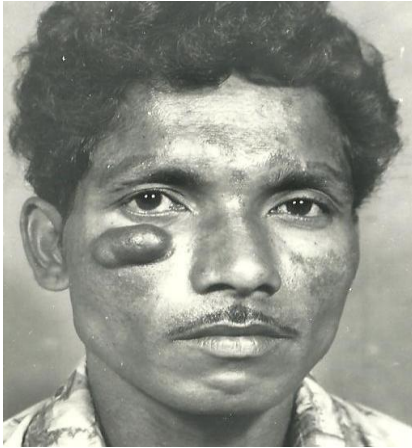1.9d

1.10 Pigmented Lesions of Face

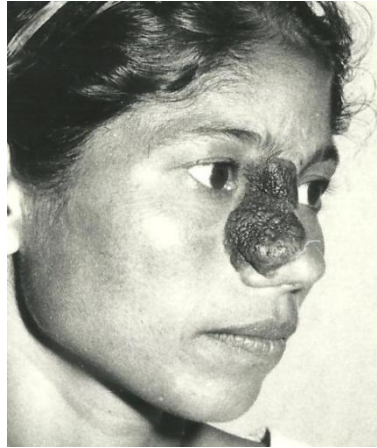Pigmented lesions of the face include naevi, moles, neuro-fibromas and vascular malformations. (1.10a, 1.10b, 1.10c, 1.10d)

They are benign, and stop growing once body growth stops. They remain asymptomatic except for cosmetic appearance.

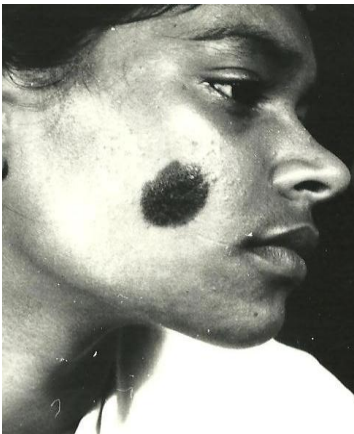Malignant change is rare in these lesions. Surgical excision and biopsy is indicated if there is a sudden change in growth, ulceration and bleeding, or appearance of symptoms such as itching or pain.



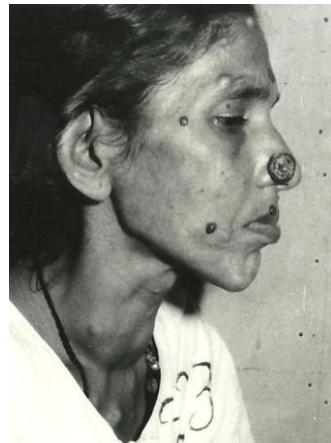1.10a



1.10b



1.10c



1.10d

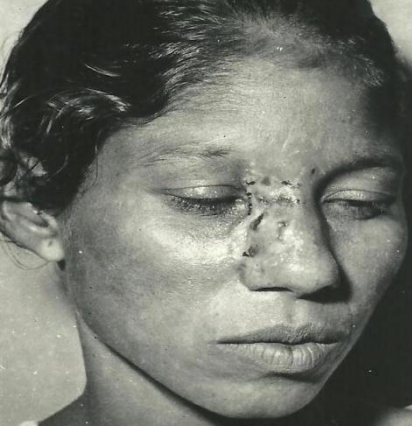1.11 Basal Cell Cancers

Basal cell carcinomas usually occur on the face above a line joining the angle of the mouth and the tragus of the ear. This area is also called 'Danger area' since its venous drainage goes to the cavernous sinus via the angular vein.

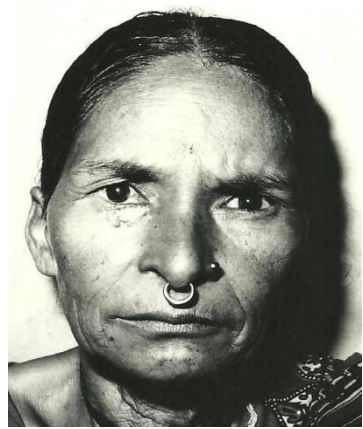
Basal cell cancer-ulcers are slow growing, have raised or rolled up edges and are locally malignant, hence metastases are rare.

They are also called 'Rodent ulcers' because of their nibbling nature and destroying everything in their path (1.11a, 1.11b, 1.11c, 1.11d).

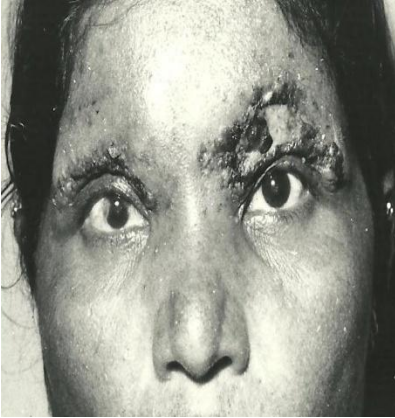Wide excision can be curative.



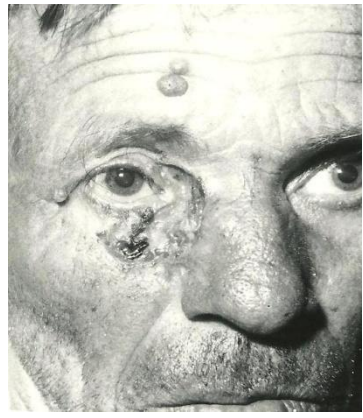
1.11a



1.11b



1.11c



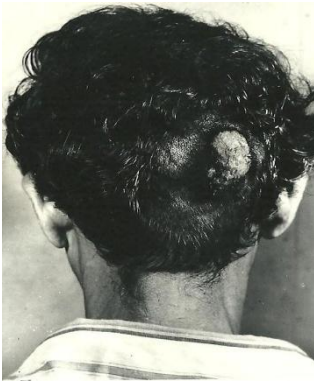1.11d

1.12 Tumors of Scalp

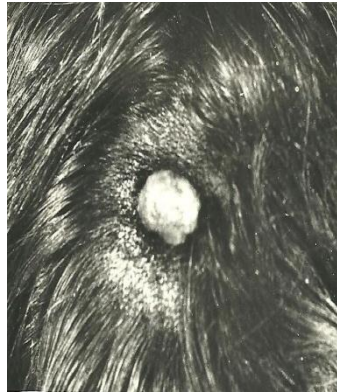These include benign papillomas (1.12a, 1.12b) and the malignant squamous cell carcinomas (1.12c).

Rare complications of sebaceous cysts can closely resemble carcinomatous lesions.

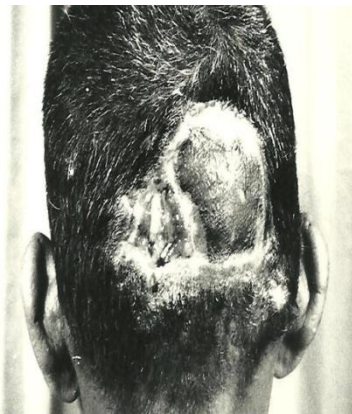‘Cock’s peculiar tumor’ is the name given to benign sebaceous adenomas (1.12d).



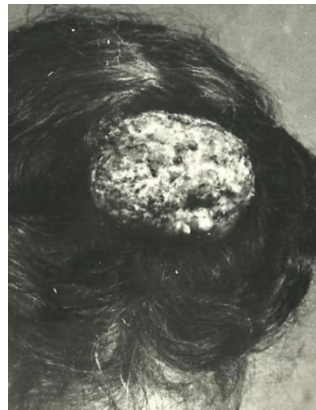
1.12a



1.12b



1.12c



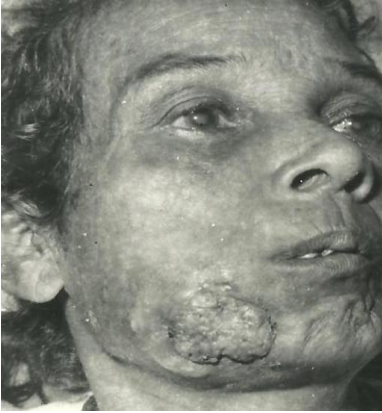1.12d

1.13 Tumors of Face

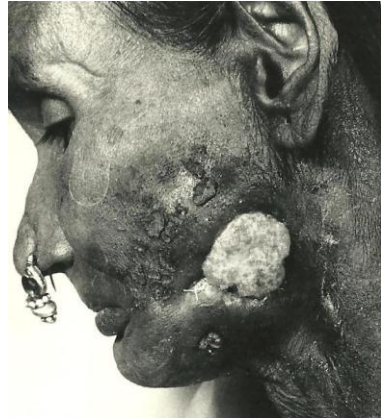Squamous cell cancers of cheek and oral cavity are quite common in communities used to chewing tobacco, and other potential carcinogenic products like ‘Gatt’ in Yemen and ‘Paan Masalas’ in India. They start in the mucosa, but eventually extend outwards involving the whole wall of the cheek and face (1.13a, 1.13b).

Smokers of cigars and pipes may develop similar malignant ulcers on the lips and the angles of the mouth (1.13c).

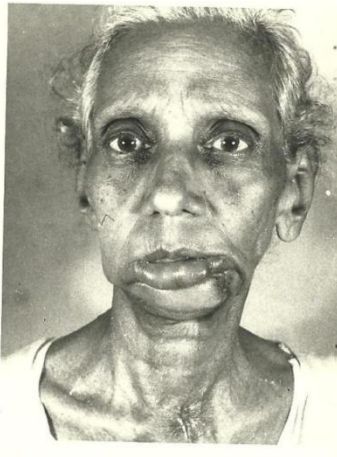Wide surgical excision of the lesion, with forehead flap reconstruction is one of the options in the management (1.13d).



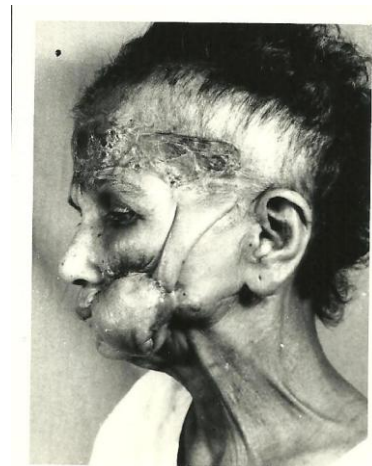1.13a



1.13b



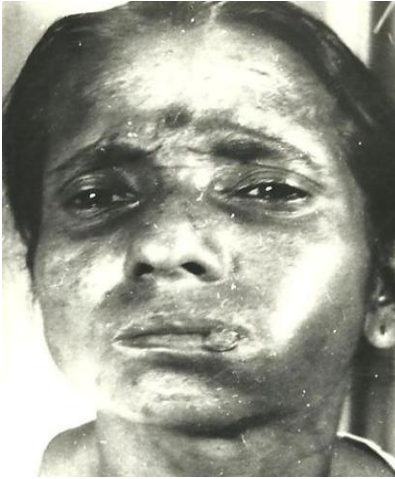1.13c



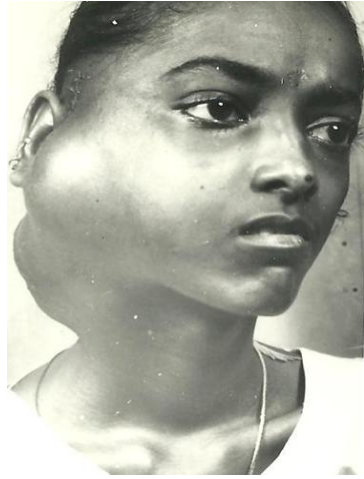1.13d

1.14 Tumors of Face [Contd.]

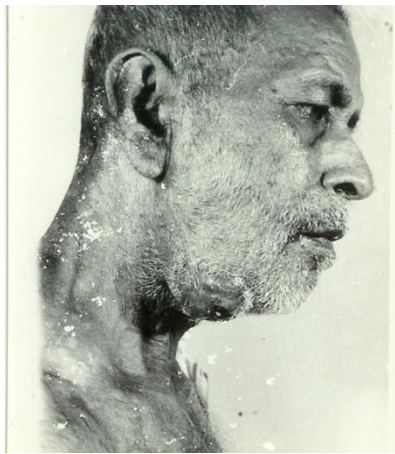
Other than carcinoma of lips (1.14a) and cheek (1.14b), which are quite common, rare tumors include neural tumors, and bony mandibular tumors (1.14c). Equally rare are the tumors of the paranasal sinuses (1.14d).



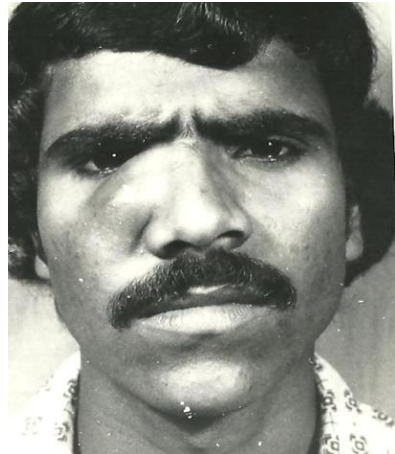
1.14a



1.14b



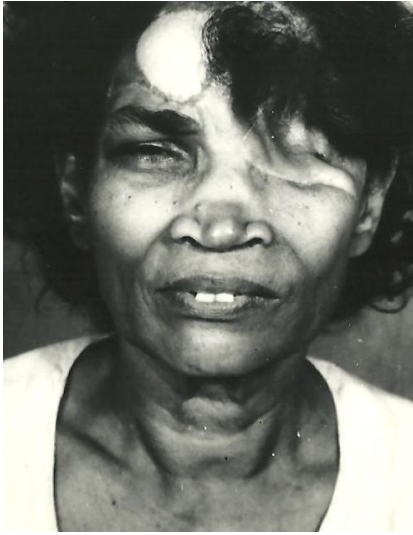1.14c



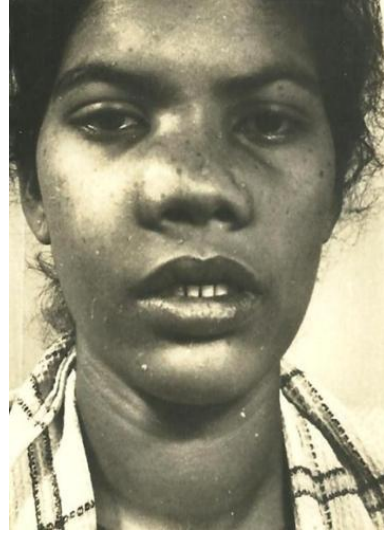1.14d

1.15 Tumors of Para-Nasal Sinuses

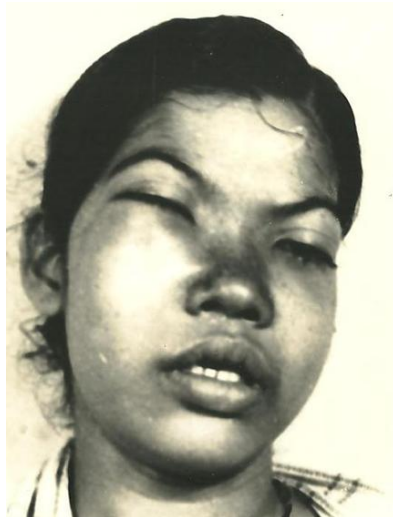Tumors of the paranasal sinuses may arise from ethmoid sinus (1.15a), or from maxillary sinus (1.15b, 1.15c).



1.15a



1.15b



1.15c

1.16 Lesions of Face

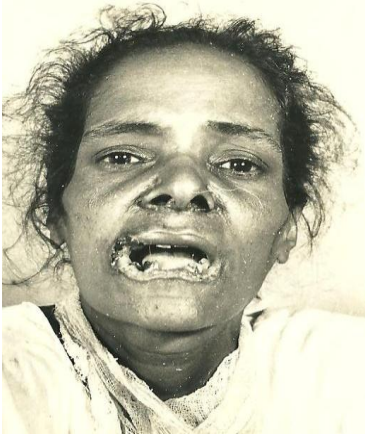Boils or the furuncles are the most common infective lesions on the hair bearing area of the face.

However muco-cutaneous junctions may be involved in primary and secondary syphilis ((1.16a, 1.16b).

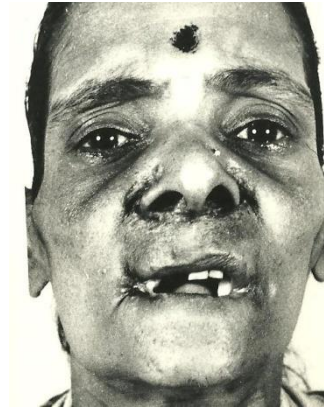‘Cancrumoris’ is a symbiotic infective gangrenous condition of the lips, cheek and face caused by combination of gram positive and gram-negative organisms as well as the anaerobes. All the tissues in its path are eaten away by the infecting organisms (1.16c).

Other examples of similar lesions are Meleney’s gangrene of the abdominal wall, Fournier’s gangrene of the scrotum and Phagedena of the penis.

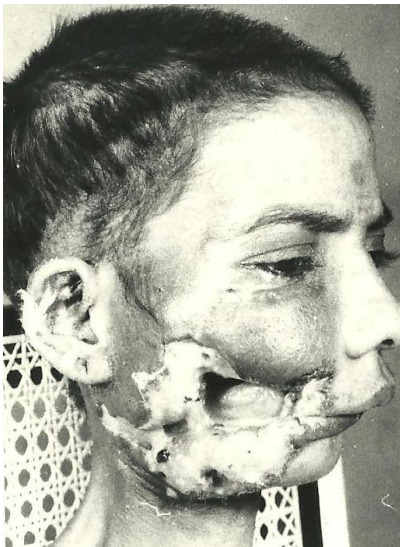Tuberculosis of buccal lymph node I extremely rare, and may lead to perforation of cheek and chronic sinus formation (1.16d).



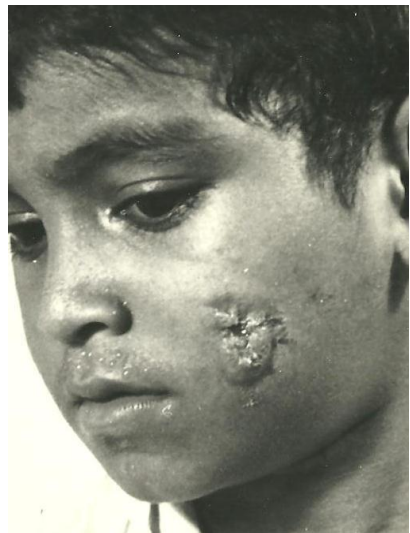1.16a



1.16b



1.16c



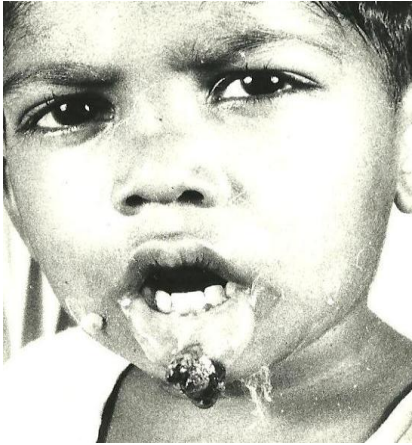
1.16d

1.17 Lesions of Face [Contd.]

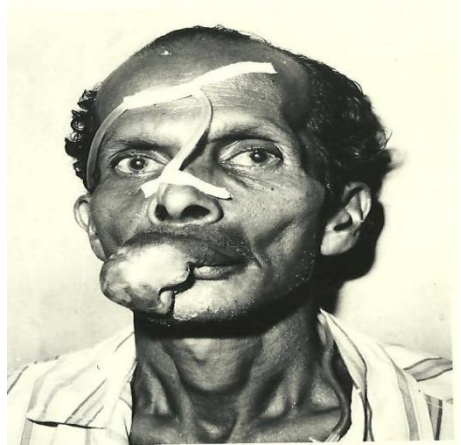
Haemophilic granuloma of the lip (1.17a), presents with bleeding lip. When it clots, secondary infection sets in leading to a granulomatous lesion. Child in this picture was suffering from haemophilia.

Septic granuloma of the lip is a rare condition. This is the result of continued lingering mild to moderate local sepsis, or presence of some foreign body. This may also arise from infection of sub mucosal cysts of lips (1.17b).

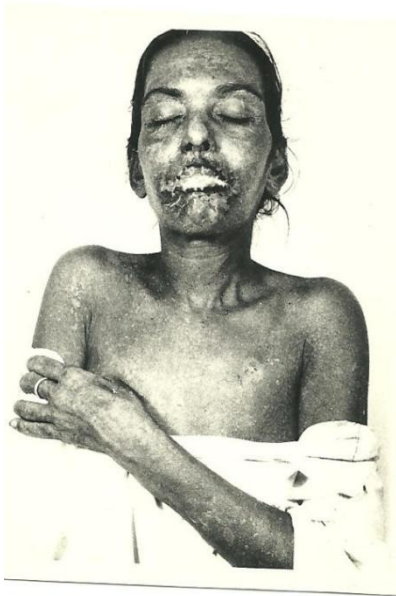Serious septic conditions and like anaphylactic reaction to drugs called Steven Johnson's syndrome presents with exfoliative lesions of skin and mucous membranes. (1.1c) and (1.1d)



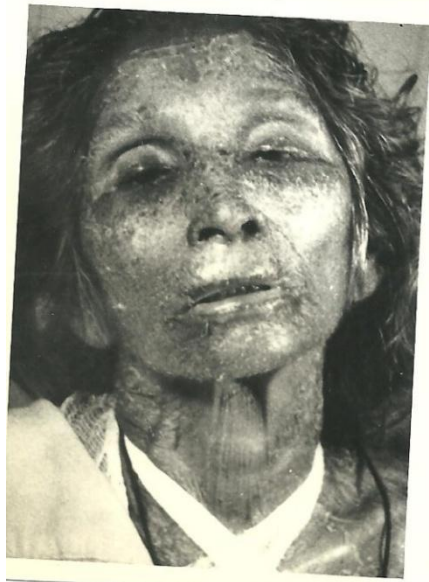1.17a



1.17b



1.17c



1.17d

